Careful Dissection of the Distal Ureter Is Highly Important in Nerve-sparing Radical Pelvic Surgery

A 3D Reconstruction and Immunohistochemical Characterization of the Vesical Plexus

Anne C. Kraima, PhD, Marloes Derks, MD,† Noeska N. Smit, MSc,‡ Cornelis J.H. van de Velde, PhD,§ Gemma G. Kenter, PhD,† and Marco C. DeRuiter, PhD**

Objective: Radical hysterectomy with pelvic lymphadenectomy (RHL) is the preferred treatment for early-stage cervical cancer. Although oncological outcome is good with regard to recurrence and survival rates, it is well known that RHL might result in postoperative bladder impairments due to autonomic nerve disruption. The pelvic autonomic network has been extensively studied, but the anatomy of nerve fibers branching off the inferior hypogastric plexus to innervate the bladder is less known. Besides, the pathogenesis of bladder dysfunction after RHL is multifactorial but remains unclear. We studied the 3-dimensional anatomy and neuroanatomical composition of the vesical plexus and describe implications for RHL.

Materials and Methods: Six female adult cadaveric pelvises were macroscopically dissected. Additionally, a series of 10 female fetal pelvises (embryonic age, 10–22 weeks) was studied. Paraffin-embedded blocks were transversely sliced in 8-μm sections. (Immuno) histological analysis was performed with hematoxylin and eosin, azan, and antibodies against S-100 (Schwann cells), tyrosine hydroxylase (postganglionic sympathetic fibers), and vasoactive intestinal peptide (postganglionic parasympathetic fibers). The results were 3-dimensionally visualized.

Results: The vesical plexus formed a group of nerve fibers branching off the ventral part of the inferior hypogastric plexus to innervate the bladder. In all adult and fetal specimens, the vesical plexus was closely related to the distal ureter and located in both the superficial and deep layers of the vesicouterine ligament. Efferent nerve fibers belonging to the vesical plexus predominantly expressed tyrosine hydroxylase and little vasoactive intestinal peptide.

Conclusions: The vesical plexus is located in both layers of the vesicouterine ligament and has a very close relationship with the distal ureter. Complete mobilization of the ureter in RHL might cause bladder dysfunction due to sympathetic and parasympathetic denervation. Hence, the distal ureter should be regarded as a risk zone in which the vesical plexus can be damaged.

Key Words: Vesical plexus, Ureter, Pelvic autonomic nerves, Radical hysterectomy, Cervical cancer

Received August 6, 2015, and in revised form December 7, 2015.
Accepted for publication February 7, 2016.

(*Int J Gynecol Cancer* 2016;00: 00–00)

*Department of Anatomy and Embryology, Leiden University Medical Center, Leiden, The Netherlands; †Department of Gynecology and Obstetrics, Academical Medical Center, Amsterdam, The Netherlands; ‡Computer Graphics and Visualization, Department of Intelligent Systems, Delft University of Technology, Delft, The Netherlands; and §Department of Surgery, Leiden University Medical Center, Leiden, The Netherlands.

Address correspondence and reprint requests to Marco C. DeRuiter, PhD, Department of Anatomy & Embryology, Leiden University Medical Center, 2300 RC Leiden, the Netherlands. E-mail: M.C.De_Ruiter@lumc.nl.

This study was fully funded by Dutch Technology Foundation (grant number 10902).

The authors declare no conflicts of interest.

ISSN: 1048-891X
DOI: 10.1097/IGC.0000000000000709

Cervical cancer is the second most common cancer in women worldwide. Five hundred thirty thousand new cases of this type of cancer leading to 275,000 deaths are being reported annually.[1] Radical hysterectomy with pelvic lymphadenectomy (RHL) is the treatment of choice for early-stage cervical cancer, where the tumor is limited to the uterus and/or upper vagina. Wertheim[2,3] described the first large series of radical hysterectomy and carried out the en bloc removal of the uterus, upper vagina, and surrounding parametrium. Meigs[4] added a pelvic lymphadenectomy to this technique, after which the Wertheim-Meigs RHL has been considered as the standard surgical treatment for early-stage cervical cancer. Later on, Okabayashi modified this technique by removing also the deep layers of the vesicouterine ligament (VUL), allowing complete separation of the bladder with the ureter from the lateral sides of the cervix uteri.[5] Additional modifications of the technique of RHL have been described that differ mainly in the extent of parametrectomy.

Nowadays, the oncological outcomes of RHL for early-stage cervical cancer are good with regard to local recurrence and survival rates.[6] This has drawn attention to the postoperative quality of life of women with cervical cancer and requiring radical pelvic surgery. It is well known that RHL can lead to significant postoperative morbidity. Lower urinary tract dysfunction, such as urinary incontinence and voiding difficulties, has been frequently reported after RHL and is mainly caused by surgical damage of the pelvic autonomic nerves.[7] The acknowledgement of surgical autonomic nerve disruption as the main factor contributing to postoperative morbidity has led to the development of nerve-sparing RHL techniques.[8] Several nerve-sparing techniques have been described in the literature and seem to be efficient and oncologically safe in early-stage cervical cancer.[6] Based on the operative classification system of Piver et al,[9] which was used to assess the radicality in RHL, Querleu and Morrow[10] published a new operative classification system. This revised classification system also considered the importance of surgical preservation of the pelvic autonomic nerves and is now internationally accepted. Nevertheless, it is of crucial importance to have an excellent understanding of the anatomy of the pelvic autonomic network to perform good-quality nerve-sparing RHL.

The pelvic autonomic nerves form an extensive network. It includes the superior hypogastric plexus (SHP), the hypogastric nerves (HNs), the pelvic splanchnic nerves, and the inferior hypogastric plexus (IHP) and its branching nerve fibers that essentially innervate the pelvic viscera.[11] Although the pelvic autonomic network has been studied extensively, the nerve fibers that branch from the IHP to innervate essentially the pelvic organs have gained far less attention. The course of the neurovascular bundles in males is well described, yet in females, the course of the nerve branches innervating the bladder and genital organs is less known.[12]

The aim of this study was to reveal the 3-dimensional anatomy of the nerve fibers belonging to the vesical plexus that branch off the IHP to innervate the bladder. In addition, we aimed to elucidate the neuroanatomical composition of the vesical plexus so as to relate postoperative complications to their nature. Forthcoming implications for nerve-sparing RHL are described.

MATERIALS AND METHODS

Materials

Adult Cadaveric Specimens

Six female human adult cadaveric pelvises were studied at the department of anatomy and embryology at Leiden University Medical Center. These materials were obtained through strict body donation legislation and regulations, which is subject to the Dutch national law. The donor bodies have been collected for medical research and education purposes after informed consent was given before death. None of the bodies had a history of pelvic surgery or pelvic pathology at post mortem examination. The donated bodies were preserved by injection of an embalming fluid in the femoral artery. After fixation, 5 female pelvises were transected midsagittally, and one female cadaver was left intact. All cadaveric pelvises were studied by imitating the initial steps of total mesorectal excision as described by Heald et al.[13] Photographs were taken with a Sony Cybershot DSC-H50 (Tokyo, Japan). One female cadaveric pelvic specimen was used to collect a tissue block comprising the distal ureter and surrounding VUL. This tissue block was dehydrated in graded ethanol and xylene, and embedded in paraffin.

Fetal Cadaveric Specimens

To further investigate the pelvic autonomic nerves, elucidate their neuroanatomical composition, and create a 3-dimensional (3D) reconstruction, a developmental series of 10 human female fetuses with embryonic ages of 10, 10.5, 11, 12, 14, 15, 16, 19, 20, and 22 weeks was studied from collections in the departments of anatomy and embryology, Leiden University Medical Centre and Academical Medical Center and from collections in the University of Warsaw in Poland. We specifically chose to study these materials, as the usage of embryos allowed accurate exploration of the 3D anatomy of the complete pelvic autonomic network in relation to all pelvic organs. All fetuses were obtained with informed consent after miscarriage or legal abortion according to the Dutch national law or after ethical approval was granted. No congenital pelvic malformations were discovered. The bony pelvises of the fetuses aged 14 and 15 weeks were removed, whereas the other fetuses were decalcified in an ethyldiaminetetraacid (EDTA) 10% solution for 72 hours. The fetal pelvises were dehydrated in graded ethanol and xylene, and embedded in paraffin blocks.

Immunohistochemical Staining

The female cadaveric tissue block was cut in 7-μm sections. The sections were stained with hematoxylin and eosin (H&E).

The paraffin blocks of the fetal specimens were serially cut in transverse sections of 8 and 10 μm and alternately stained with H&E. Additional sections were selected for immunohistochemical analysis. Mouse anti-alpha–smooth muscle actin (Sigma-Aldrich, A-2547), rabbit anti-S-100 (S100; DAKO, Z-031101), sheep anti–tyrosine hydroxylase (TH; Fischer Emergo, PA-14679) and rabbit anti–vasoactive intestinal peptide (VIP; LifeSpan Biosciences, AB-8556) were used to identify smooth muscle fibers, peripheral nerves, sympathetic adrenergic fibers, and postganglionic parasympathetic fibers, respectively. The immunohistochemical protocol has been described elsewhere.[14]

Image Acquisition

Consecutive sections of the fetus aged 14 weeks were used to create a 3D reconstruction. Micrographs were made with an Olympus AX70 microscope and Olympus D12 camera. One in 20 sections was used for the reconstruction creating an cross-sectional interval of 160 μm. Amira software package version 5.3.3 (Template Graphics Software, Visage Imaging, San Diego, CA) was used for the 2-dimensional labeling of anatomical structures. With DeVIDE software,[15] the 3D volume was rendered and an interactive PDF file was created.

RESULTS

Adult Cadaveric Specimens

On a macroscopic level, the "holy plane" of total mesorectal excision was recognized in all pelvises between the parietal and visceral fascia as described by Heald et al.[13] The rectum and surrounding mesorectum were mobilized by sharp dissection along the mesorectal fascia until the levator ani muscle. The SHP was located ventrally to the aortic bifurcation and sacral promontory and continued in the bilaterally located HN. This descended to the pelvis within the extraperitoneal connective tissues located posteriorly to the ureter. The HN fused with the pelvic splanchnic nerves, arising from the second, third, and fourth sacral roots, to form the IHP. In all female cadaveric pelvises, the IHP appeared as a meshlike plexus consisting of multiple nerve fibers within adipose tissues, extending from the rectum to the uterus and upper vagina. The IHP was located medially and inferiorly to the ureter and internal iliac artery. The uterine artery superiorly crossed the ureter to supply the cervix uteri and uterus. At this point, small nerve fibers branched off the IHP and ran over the ureter to innervate the bladder at the level of the ureteral orifice (Fig. 1). These nerve fibers belonged to the vesical plexus and were detected to run in both the superficial and deep layers of the VUL, also referred to as the ventral parametrium.

The H&E-stained sections of the female cadaveric tissue block confirmed the presence of nerve fibers in both layers of the VUL. Multiple ganglionated nerve fibers were related closely to the ureter (Fig. 2).

Fetal Cadaveric Specimens

In all fetal specimens, nerve branches from the IHP were related very closely to the distal ureter. The HN coursed along the dorsolateral rectum and appeared as 2 small neural networks rather than 2 single nerves. The IHP was located inferiorly to the ureter and appeared as a square-shaped plexus existing of multiple ganglia and nerve fibers. Its widest edges extended from the mid-rectum to the cervix uteri and upper vagina. From the superior part of the IHP, a few nerve fibers branched off passing the ureter at its medial and lateral sides heading toward the bladder (Figs. 3A and 4). From the middle part of the IHP, multiple nerve fibers branched off passing the ureter again at both sides and continued to run in close relation to the ureter until its insertion in the bladder. Nerve branches passing the ureter medially were located in the rectal pillars. The ureter divided the VUL into a superficial and deep layer. We referred to part of the ureter running in the VUL as the distal ureter. In all fetuses, an evident plexus was located in the superficial layer of the VUL anteriorly to the distal ureter directly after the crossing of the uterine artery with the ureter. This plexus was identified as the vesical plexus formed by those nerve fibers that innervated the bladder. These nerve fibers proceeded directly from the IHP to the bladder via the superficial and deep layers of the VUL and expressed mostly TH revealing their nature as being postganglionic sympathetic nerve fibers (Figs. 3B, C and Fig. 4). From the inferior part of the IHP, nerves branched off and ran inferior to the ureteral orifice to innervate the bladder neck, urethra, and external genital organs. These nerve fibers expressed both TH and VIP, revealing their nature as being postganglionic sympathetic and postganglionic parasympathetic nerve fibers. The results have been represented in a 3D reconstruction that can be interactively explored online at http://graphics.tudelft.nl/vesicalplexus.

DISCUSSION

Up to now, substantial progress has been made in identifying risk zones where pelvic autonomic nerves are prone to surgical damage. Main focus has always been on the surgical preservation of the SHP, HN, pelvic splanchnic nerves, and IHP,[16] although the importance of preserving the nerve fibers that branch off the IHP and essentially innervate pelvic viscera is remarkably less emphasized. General anatomy textbooks do not specifically focus on these nerve branches and might depict them imprecisely as a fan-shaped continuation of the IHP.[11] As such, their contribution to optimal functioning of pelvic viscera can be easily forgotten about. The lack of or loss of accurate knowledge of nerve branches from the IHP innervating the pelvic viscera must be reversed to optimize nerve-sparing RHL.

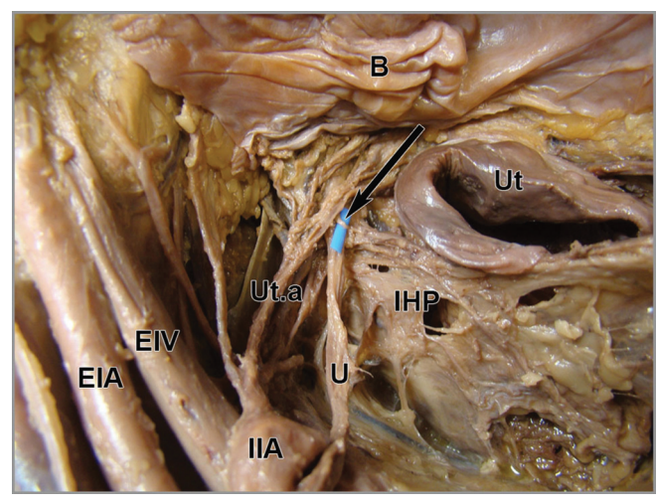

FIGURE 1. Female vesical plexus. Superior view on the left side of a female pelvis. The uterus (Ut) and inferior hypogastric plexus (IHP) are retracted to the right side. The blue ligature and arrow depict a bundle of nerve fibers from the IHP running over the ureter to innervate the bladder. Note the relation of the efferent fibers with the uterine artery (Ut.a). The IHP is being pulled to the right to maximally expose the efferent fibers. B, bladder; EIA, external iliac artery; EIV, external iliac vein; IIA, internal iliac artery; U, ureter; Ut, uterus.

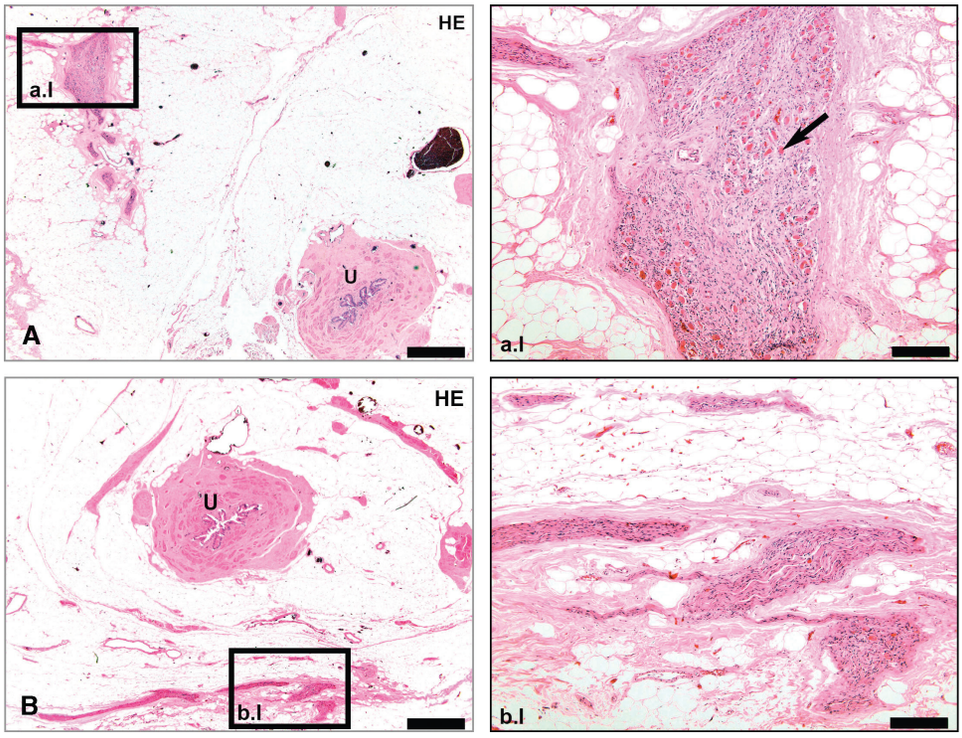

FIGURE 2. The vesical plexus runs closely to the distal ureter. This figure shows nerve fibers in relation to the distal ureter located in the whole vesico-uterine ligament of the female cadaveric tissue block. Details of inset A.I reveal the presence of a nerve plexus including multiple ganglia (indicated by the arrow). Details of inset B.I demonstrate multiple nerve fibers running very closely to the distal ureter. Scale bar in overview, 1 mm; detail, 200 μm.

In the present work, we studied the 3D course, topology, and neuroanatomical composition of the vesical plexus, which forms a group of multiple efferent and afferent nerve fibers that innervate the bladder.

This study has revealed that the vesical plexus runs in close relation to the distal ureter in both the superficial and deep layers of the VUL. The efferent nerve fibers are of postganglionic sympathetic and parasympathetic nature, implying that surgical damage of the vesical plexus may lead to both sympathetic and parasympathetic denervation of the bladder. Indeed, urinary incontinence is frequently reported after radical pelvic surgery.[7,17] All gynecologists operating in the pelvis should realize that preservation of the SHP, HN, pelvic splanchnic nerves, and IHP does not automatically warrant sufficient postoperative bladder function when the vesical plexus could still be damaged.

Although the pelvic autonomic network has been often studied, many researchers have not paid special attention to the nerve fibers branching from the IHP and consequently lacked in describing the vesical plexus.[18–21] Two researchers previously reported on the course and topology of efferent nerve fibers from the IHP. Based on macroscopic dissections of female cadaveric specimens, Mauroy et al[22,23] described the anatomy of the various efferent nerve fibers from the IHP innervating the urogenital organs and identified anatomical reference points that could be helpful in pelvic surgery as to enhance nerve-sparing surgical techniques. We fully agree with their reference to the ureter as the vector for vesical nerve fibers. In their studies, the bulk of the vesical plexus was allocated inferiorly to the ureterovesical junction from where a medial and lateral nerve branch ran along the lateral edges of the vesical trigone and bladder neck, respectively. They did not report on the presence of vesical nerve fibers anteriorly to the ureter.[22,23] Yamaguchi et al[24] found sex differences in the distribution of nerve fibers to the bladder and explicitly mentioned that these nerve fibers might run along the distal ureter in females. Contrary to the results of Mauroy et al,[22,23] we observed a slightly more variable pattern of nerve fibers running along the distal ureter. In all fetal specimens, an evident plexus was identified anteriorly to the distal ureter, whereas the vesical plexus in the adult specimens consisted of several loose nerve branches rather than a firm plexus. An explanation could be that the growth of extraperitoneal tissues in postnatal development causes the developing ureter to break up the vesical plexus and subsequently creates a more widespread distribution of the vesical nerve fibers. This also helps to understand the difficulty in recognizing the vesical plexus during macroscopic anatomical dissections and RHL. It is therefore of crucial importance to be aware of the detailed anatomy of the vesical plexus. According to Walsh "…we only see what we look for, but we only look for what we know".[12]

The results of this study might have significant clinical consequences for the surgical treatment of cervical cancer. The operative classification system of Querleu and Morrow[10] describes 4 types of RHL techniques. In 2 types, the ureter is

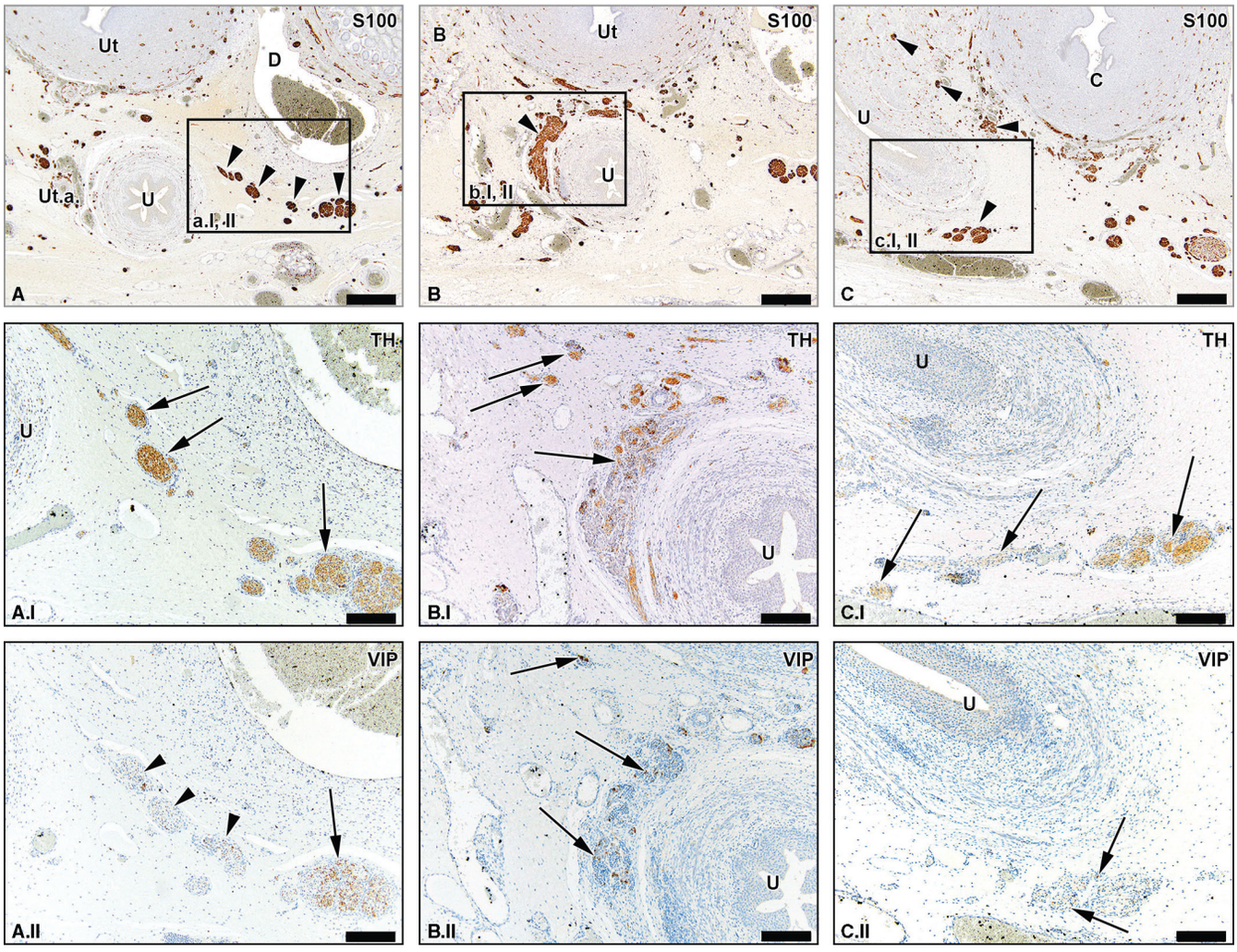

FIGURE 3. Immunohistochemical characterization of the vesical plexus. The course of efferent fibers from the IHP in a female fetus aged 15 weeks is shown here. A-C, Consecutive inferior levels. A, The arrowheads point out the efferent fibers from the IHP, which in this fetus pass the ureter on its medial side. Note the crossing of the uterine artery (Ut.a) with the ureter. The efferent fibers express mostly TH (left, 2 arrows in A.I) and little VIP, arrowheads in A.II). On the contrary, the IHP contains both TH and VIP (right arrow, A.I and A.II). At a more inferior level, an evident plexus is seen anterior to the ureter (arrowhead, B). The efferent fibers innervating the bladder express mostly TH (arrows in B.I) and little VIP (arrows in B.II). At the level of the ureteral orifice, efferent fibers can be detected at both sides of the ureter. Thicker fibers pass the ureter on its lateral side, the posterolateral wall of the bladder (lower arrowhead in C), whereas more minuscule fibers pass the ureter on its medial side to innervate the posterior bladder wall (upper arrowheads in C). These efferent fibers express mostly TH (arrows in C.I) and little VIP (arrows in C.II). Ut, uterus; D, Douglas pouch; U, ureter; B, bladder. Scale bar overview, 500 μm; detail, 200 μm.

completely mobilized; and in one type, the ureter is unroofed and rolled laterally. The presence of autonomic nerves in the deep layers of the VUL has been previously acknowledged.[6,16,25] Following this, resection of the deep layers of the VUL has been correctly recognized as a potential nerve-injuring step in RHL.[6] However, we have demonstrated that the vesical plexus is also present in the superficial layers of the VUL. The 3D reconstruction of the fetal autonomic network has clearly shown that it actually encircles the distal ureter. This means that preservation of the vesical plexus is only achievable in 1 of the 4 types of RHL, as proposed by Querleu and Morrow.[10] Gynecologists who choose to remove only the superficial layers of the VUL, aiming to preserve the vesical nerve fibers in the deep layers of the VUL, are likely to end up (partially) disrupting the vesical plexus anyway.[6] Bladder dysfunction, such as urge incontinence, stress incontinence, voiding difficulties, and dysuria, is often reported after a Wertheim-Okabayshi RHL, in which the ureter is completely mobilized.[7]

The Leiden TNM classification has been developed to describe the extensiveness of parametrectomy in all directions,[26] based on the well-known TNM classification system for the description of various tumors in categories for tumor extension

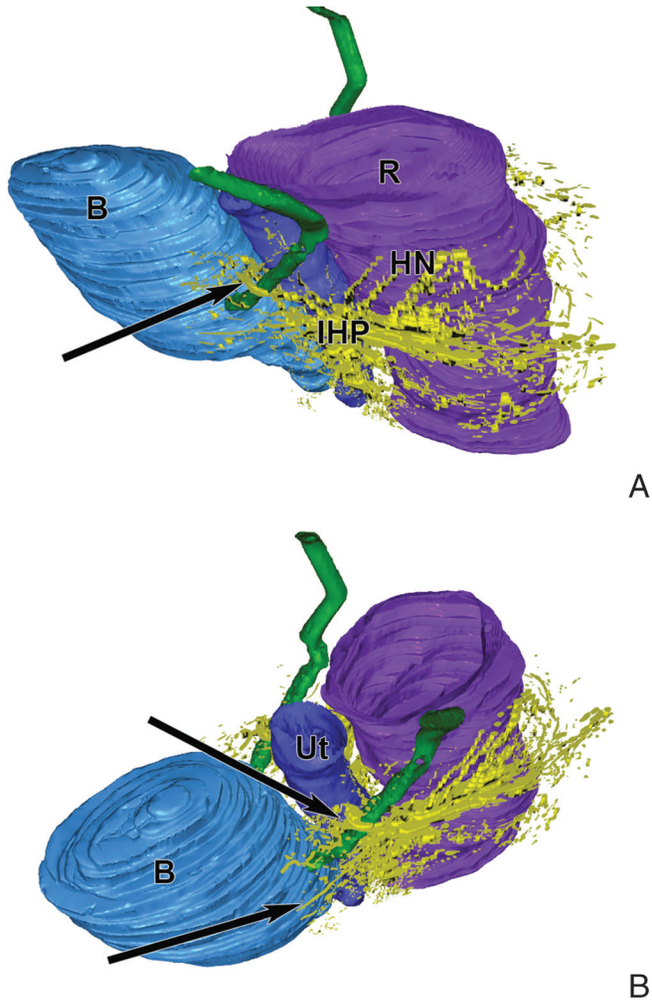

FIGURE 4. Three-dimensional reconstruction of the pelvic autonomic network. Three-dimensional reconstruction of the pelvic autonomic network of the fetus aged 14 weeks. The bladder is depicted in light blue, the uterus in dark blue, the rectum in purple, the ureter in green, and the autonomic nerves in yellow. A, Posterolateral view, in which the arrow indicates the nerve fibers from the middle part of the IHP surrounding the distal ureter. B, Anterolateral view, in which the distribution of nerve fibers in relation to the distal ureter can be explored. The upper arrow shows the plexus located on top of the ureter in the superficial layer of the VUL, whereas the lower arrow points out nerve fibers running in the deep layer of the VUL.

(T), nodal disease (N), and distant metastasis (M). Figure 5 schematically shows the course of the pelvic autonomic nerves in relation to the ventral, lateral, caudal, and dorsal extensions of the parametrium. The distal ureter, running in the VUL, should be regarded as an important risk zone in which the vesical plexus could be surgically damaged.

Malignant spread of cervical cancer occurs mainly via local tumor growth and/or lymphatics, underlining the importance of accurately removing the draining lymph vessels besides pelvic lymph nodes. This principle of RHL should never be neglected by any technique aiming at preservation of the autonomic nerves. A recent immunohistochemical study

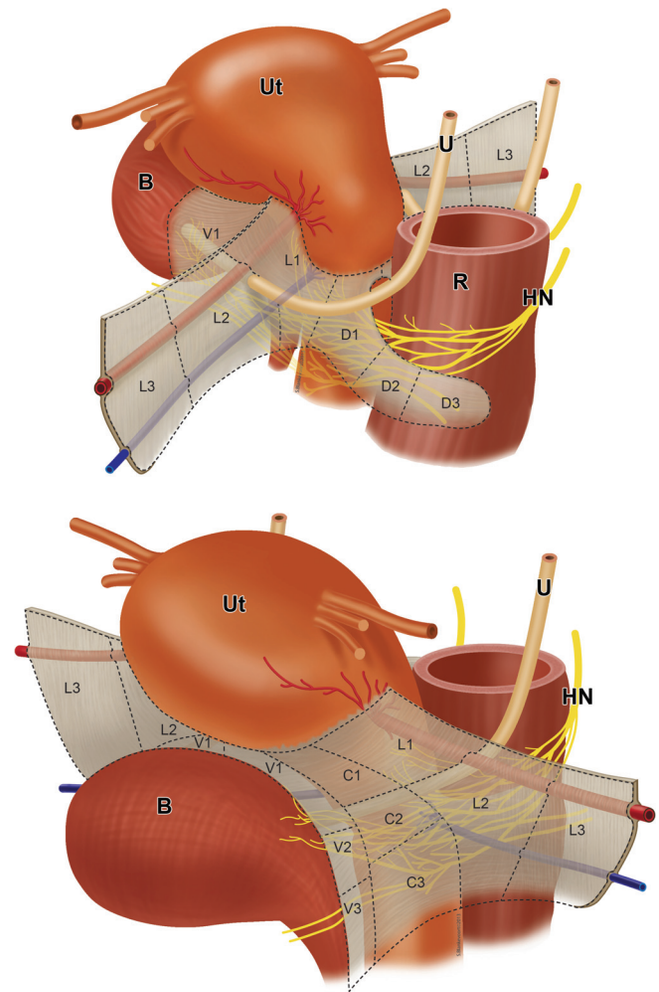

FIGURE 5. Pelvic autonomic network in relation to the different extensions of the parametrium. The parametrium can be divided into 4 surgical extensions based on the Leiden TNM classification system. Ventral (V) 1, superficial layer of the VUL; V2, medial part of the deep layer of the VUL; V3, lateral part of the deep layer of the VUL. Lateral (L) 1, medial to the ureter; L2, between the ureter and pelvic side wall; L3, until the pelvic side wall. Caudal (C) 1, above the ureter; C2, above the deep uterine vein; C3, below the deep uterine vein. Dorsal (D) 1, between the uterus and rectum; D2, at the anterior rectal border; D3, halfway of the rectal circumference. Note that the ureter passes through the lateral, ventral, and upper caudal parametria. The IHP is located in the dorsal, lateral, and upper caudal parametria, caudal to the ureter. The vesical plexus is located in the ventral parametrium in V1 and V2 superiorly and inferiorly to the distal ureter. The neurovascular bundles run more caudally in V3. R, rectum.

of human fetal cadaveric specimens has shown that the lymphatic drainage pathways of the cervix uteri do not run via the VUL.[27] Thus, one could carefully argue that nerve-sparing RHL in early-stage cervical cancer might be feasible by leaving the whole VUL and avoiding mobilization of the distal ureter. Caution is of essence here, as lymphatic drainage pathways of the cervix uteri should be confirmed in human adults before modifying RHL techniques.

Furthermore, immunohistochemical analysis of human fetuses forms a valuable method to study large anatomical regions in relatively small specimens. Although the fetal anatomy is not comparable to that of an adult, the pelvic neural network does not undergo fundamental changes from a gestational age of 8 weeks throughout fetal development.[28,29] The neuroanatomical characterization of the vesical plexus is complex. The presence of postganglionic sympathetic fibers is with no doubt confirmed by the expression of TH, whereas the detection of parasympathetic fibers is less straightforward. Vasoactive intestinal peptide mediates parasympathetic function of pelvic viscera but is only expressed in postganglionic parasympathetic fibers.[30] The VIP-positive fibers as detected in the vesical plexus can be interpreted as postganglionic parasympathetic fibers, but VIP might be expressed on sensory afferent C-fibers as well.[30] Current immunohistochemical techniques do not allow exclusive identification of sensory afferent fibers.[30] Besides, the restrictive usage of immunohistochemistry in the fetal cadaveric specimens hampered to investigate the presence of sensory afferent nerve fibers in the vesical plexus. Although the nature of the aforementioned bladder impairments presumes the presence of sensory fibers as well, this is yet to be revealed.

In conclusion, the vesical plexus is closely related to the distal part of the ureter and runs in both the superficial and deep layers of the VUL before innervating the bladder. Efferent nerve fibers belonging to the vesical plexus are postganglionic sympathetic and postganglionic parasympathetic fibers, implying that surgical disruption of the vesical plexus might result in bladder dysfunction owing to both sympathetic and parasympathetic denervation. The distal ureter should be regarded as an important risk zone in which the vesical plexus could be surgically damaged. If gynecologists free up the ureter until its insertion in the bladder, the vesical plexus will be consequently sacrificed.

ACKNOWLEDGMENTS

The authors thank Adam Kolesnik from the University of Warsaw in Poland for providing them with 4 fetuses, and Conny van Munsteren for her help in processing and sectioning the fetal specimens.

REFERENCES

1. Ferlay J, Shin HR, Bray F, et al. *Cancer Incidence and Mortality Worldwide:* IARC CancerBase No 10 [Internet]. Lyon, France: IARC; 2008.
2. Wertheim E. A discussion on the diagnosis and treatment for cancer of the uterus. *BMJ.* 1905;2:689–704.
3. Wertheim E. The extended abdominal operation for carcinoma uteri (based on 500 operative cases). *Am J Obstet Dis Women Child*. 1912;66:169–232.
4. Meigs JV. The radical operation for cancer of the cervix. *Am J Roentgenol Radium Ther*. 1947;57:679–684.
5. Okabayashi H. Radical abdominal hysterectomy for cancer of the cervix uteri, modification of the Takayama operation. *Surg Gynecol Obstet*. 1921;33:335–341.
6. Rob L, Halaska M, Robova H. Nerve-sparing and individually tailored surgery for cervical cancer. *Lancet Oncol*. 2010;11:292–301.
7. Hazewinkel MH, Sprangers MA, van der Velden J, et al. Long-term cervical cancer survivors suffer from pelvic floor symptoms: a cross-sectional matched cohort study. *Gynecol Oncol*. 2010;117:281–286.
8. de Kroon CD, Gaarenstroom KN, van Poelgeest MI. Nerve sparing in radical surgery for early-stage cervical cancer: yes we should! *Int J Gynecol Cancer*. 2010;20:S39–S41.
9. Piver MS, Rutledge F, Smith JP. Five classes of extended hysterectomy for women with cervical cancer. *Obstet Gynecol*. 1974;44:265–272.
10. Querleu D, Morrow CP. Classification of radical hysterectomy. *Lancet Oncol*. 2009;115:314–315.
11. Standring S. *Gray's Anatomy*, 40th ed. London, UK: Churchill Livingstone Elsevier; 2008.
12. Walsh PC, Schlegel PN. Radical pelvic surgery with preservation of sexual function. *Ann Surg*. 1988;208:391–400.
13. Heald RJ. The 'Holy Plane' of rectal surgery. *J R Soc Med*. 1988;81:503–508.
14. Kraima AC, van Schaik J, Susan S, et al. New insights in the neuroanatomy of the human adult superior hypogastric plexus and hypogastric nerves. *Auton Neurosci*. 2015;189:60–67.
15. Botha CP, Post FH. *Hybrid Scheduling in the DeVIDE Dataflow Visualisation Environment*. Erlangen: SCS Publishing House; 2008:309–322.
16. Trimbos JB, Maas CP, DeRuiter MC. A nerve-sparing radical hysterectomy: guidelines and feasibility in Western patients. *Int J Gynecol Cancer*. 2001;11:180–186.
17. Laterza RM, Sievert KD, de Ridder D, et al. Bladder function after radical hysterectomy for cervical cancer. *Neurourol Urodyn*. 2015;34:309–315.
18. Tong XK, Huo RJ. The anatomical basis and prevention of neurogenic voiding dysfunction following radical hysterectomy. *Surg Radiol Anat*. 1991;13:145–148.
19. Baader B, Herrmann M. Topography of the pelvic autonomic nervous system and its potential impact on surgical intervention in the pelvis. *Clin Anat*. 2003;16:119–130.
20. Spackman R, Wrigley B, Roberts A. The inferior hypogastric plexus: a different view. *J Obstet Gynaecol*. 2007;27:130–133.
21. He JH, Wang Q, Cai QP, et al. Quantitative anatomical study of male pelvic autonomic plexus and its clinical potential in rectal resection. *Surg Radiol Anat*. 2010;32:783–790.
22. Mauroy B, Bizet B, Bonnal JL. Systematization of the vesical and uterovaginal efferences of the female inferior hypogastric plexus (pelvic): applications to pelvic surgery on women patients. *Surg Radiol Anat*. 2007;29:209–217.
23. Mauroy B, Demondion X, Drizenko A, et al. The inferior hypogastric plexus (pelvic plexus): its importance in neural preservation techniques. *Surg Radiol Anat*. 2003;25:6–15.
24. Yamaguchi K, Kobayashi M, Kato T. Origins and distribution of nerves to the female urinary bladder: new anatomical findings in the sex differences. *Clin Anat*. 2011;24:880–885.

25. Fujii S, Takakura K, Matsumura N, et al. Anatomic identification and functional outcomes of the nerve sparing Okabayashi radical hysterectomy. *Gynecol Oncol*. 2007;107:4–13.
26. Trimbos JB. TNM-like classification of radical hysterectomy. *Gynecol Oncol*. 2009;113:397–398.
27. Kraima AC, Derks M, Smit NN, et al. Lymphatic drainage pathways from the cervix uteri: implications for radical hysterectomy? *Gynecol Oncol*. 2014;132:107–113.
28. Arango-Toro O, Domenech-Mateu JM. Development of the pelvic plexus in human embryos and fetuses and its relationship with the pelvic viscera. *Eur J Morphol*. 1993;31:193–208.
29. Fritsch H. Topography of the pelvic autonomic nerves in human fetuses between 21–29 weeks of gestation. *Anat Embryol (Berl)*. 1989;180:57–64.
30. Jänig W. *The Integrative Action of the Autonomic Nervous System*. Cambridge University Press, Cambridge, UK; 2006.

